



# Esthetic evaluation of implants vs canine substitution in patients with congenitally missing maxillary lateral incisors: Are there any new insights?

Ute Schneider,<sup>a</sup> Lorenz Moser,<sup>a</sup> Marzia Fornasetti,<sup>b</sup> Michele Piattella,<sup>c</sup> and Giuseppe Siciliani<sup>d</sup>  
Ferrara, Bolzano, and Vicenza, Italy

**Introduction:** The aims of the study were to determine how a panel of orthodontists, dentists, and laypersons rated the esthetic appeal of dentitions after orthodontic space closure by canine substitution compared with space opening and replacement of missing maxillary lateral incisors by implant-borne crowns and to compare the outcome with the results of a study in the United States in 2005. **Methods:** A series of 9 posttreatment intraoral frontal photographs was presented to 87 orthodontists, 100 general dentists, and 100 laypersons. The photographs represented dentitions with either single-tooth implants or canine substitutions for missing maxillary lateral incisors and dentitions with no missing teeth. Each photograph was rated independently by assigning a number between 1 (best) and 5 (worst) for a series of 7 bipolar adjectives. Two-way analysis of variance and Tukey post hoc tests were performed to assess differences in intragroup and intergroup preferences for the various treatment options. Subsequently, the mean scores were compared with the mean scores in the study from 2005. **Results:** Highly significant improvements ( $P < 0.0001$ ) in the esthetic outcome for implants were found in all respondent groups when compared with the study from 2005. To date, orthodontists and dentists rank implants and canine substitution as equally pleasing, but laypersons prefer space closure. **Conclusions:** Perceptions of dental esthetics can vary between dental professionals and laypersons. Investigating each patient's esthetic expectations is thus important, but in the patient's best interest, esthetic and functional aspects should be carefully weighed during comprehensive treatment planning. (Am J Orthod Dentofacial Orthop 2016;150:416-24)

A genesis of one or both maxillary lateral incisors is a frequent clinical finding, which affects approximately 2% of the population.<sup>1-4</sup> As orthodontists, we are faced with 2 treatment options: to open space for a prosthetic replacement of the missing lateral incisor mostly with an implant-borne crown or to completely close the space by mesialization of the posterior teeth with the canine substituting the missing lateral

incisor. Selecting the appropriate treatment approach is a complex decision depending on the patient's existing malocclusion, growth pattern, profile, smile line, and the size, shape, and color of the canines.<sup>5</sup> It is important to consider treatment options that lead to functionally, esthetically, and periodontally acceptable results and that remain stable in the long term.

The main advantage of space closure is that the entire treatment is finished with the orthodontic treatment, and this approach allows the hard and soft tissue architecture to remain in a natural state that can better respond to the changes over time. On the other hand, the canine will need reduction in the incisogingival and mesiodistal dimensions, with flattening of the labial surface, steepening of the lingual convexity, and bleaching and composite bonding or veneering to mimic the replaced tooth. The dimensions of the premolar must be increased mesiodistally and incisogingivally, and the lingual cusp will need to be reduced.<sup>6</sup>

<sup>a</sup>Visiting professor, Department of Orthodontics, University of Ferrara, Ferrara, Italy; private practice, Bolzano, Italy.

<sup>b</sup>Private practice, Vicenza, Italy.

<sup>c</sup>Private practice psychologist and freelance statistician, Ferrara, Italy.

<sup>d</sup>Chairman and director, Postgraduate School of Orthodontics, University of Ferrara, Ferrara, Italy.

All authors have completed and submitted the ICMJE Form for Disclosure of Potential Conflicts of Interest, and none were reported.

Address correspondence to: Ute Schneider, Citycenter, Via Alto Adige 40, Bolzano 39100, Italy; e-mail, [ute.moser@brennercom.net](mailto:ute.moser@brennercom.net).

Submitted, September 2015; revised and accepted, February 2016.

0889-5406/\$36.00

© 2016 by the American Association of Orthodontists. All rights reserved.

<http://dx.doi.org/10.1016/j.ajodo.2016.02.025>

The alternative approach consists of space opening by distalizing the canine into its natural position and preparing for prosthetic replacement,<sup>7,8</sup> mostly dental implants, which leads to predictable and successful results, especially in patients with healthy and unrestored adjacent teeth of normal size and shape.<sup>9–11</sup> However, placing an implant in the esthetic zone is a technique-sensitive and operator-sensitive procedure with little room for error to prevent complications, such as incomplete papillary fill, alveolar bone loss, and gingival discoloration.<sup>12,13</sup> To achieve an optimal esthetic and functional result, it is often necessary to establish a coordinated, interdisciplinary approach involving an orthodontist, an oral surgeon or a periodontist, and a restorative dentist. The alveolar ridge will often require additional bony or soft tissue grafting to create a thick periodontal biotype that can withstand future resorptive processes and to guarantee excellent hard and soft tissue stability over time.<sup>14–18</sup> However, it is not possible to exclude a potentially developing infraocclusion, especially in patients with poor interincisor stability.<sup>19–22</sup>

An important aspect during treatment planning in patients with congenitally missing maxillary lateral incisors is to satisfy their esthetic demands, Nordquist and McNeill<sup>23</sup> in 1975 and Robertsson and Mohlin<sup>24</sup> in 2000 found that patients who had undergone orthodontic space closure with canine substitution were more pleased with the esthetic outcome than were patients treated with space opening and bridge work. In neither of those studies were single implants for replacement of the missing lateral incisors included.

In 2014, De-Marchi et al<sup>25</sup> found no difference in the ratings of smile esthetics in patients with implants or space closure by dentists and laypersons when evaluating photographs of the lower facial third, but these images had the risk of distracting the respondents, especially untrained laypersons, by lip fullness or skin texture and color.

A retrospective survey of 5 patients who had been treated by orthodontic space closure vs 5 patients treated with implant-borne crowns by Jamilian et al<sup>26</sup> in 2015 could not show any difference in patient satisfaction with the esthetic outcomes, but the sample size was small and not suited for any statistical analysis.

To our knowledge, the only study evaluating the esthetic appeal of implant-borne crowns and Maryland bridges vs space closure by canine substitution with intraoral frontal photographs of treated patients is a survey by Armbruster et al<sup>27,28</sup> from 2005. Photographs of dentitions with no missing teeth served as controls. A panel of orthodontists, dentists, and laypersons judged the esthetic outcomes of the different treatment modalities. All respondent groups rated prosthodontic replacement of the missing lateral incisors as the worst.

Over the last 10 years, sophisticated surgical techniques, individual abutment designs, and new prosthodontic materials to improve the long-term stability of both pink and white esthetics of implant-borne restorations have been developed.<sup>8,14–17</sup>

Therefore, the purpose of this survey was to determine (1) whether the esthetic appreciations of orthodontists, dentists, and laypersons for space closure with canine substitution, for space opening with prosthodontic replacement, and for a dentition with no missing teeth had substantially changed from 2005 to 2015; and (2) whether the implementation of the latest improvements in implantology and prosthodontics has led to an overall improvement of the esthetic outcome of implant-borne crowns for congenitally missing maxillary lateral incisors compared with the study by Armbruster et al<sup>27,28</sup> from 2005.

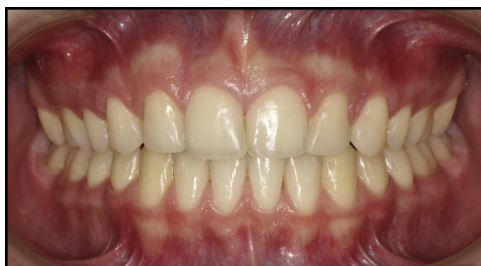## MATERIAL AND METHODS

A series of 9 intraoral frontal photographs was evaluated by a panel of 87 orthodontists, 100 general dentists, and 100 laypersons. Three clinical examples each for space closure with canine substitution for missing maxillary lateral incisors, space opening and replacement of the missing lateral incisors with implant-borne crowns, and an orthodontically treated dentition with no missing teeth in central occlusion were assessed (Figs 1–9). These 9 examples had been judged as the best treatment outcomes by a panel of 4 orthodontists and 2 general dentists with more than 25 years of experience in their fields, from the authors' (U.S., L.M.) archives for records of patients who had finished treatment at least 12 months previously. All patients had signed an informed consent form before treatment that their records might be used for scientific purposes later. The study was approved by the board of the dental faculty and the ethics committee of the University of Ferrara in Ferrara, Italy.

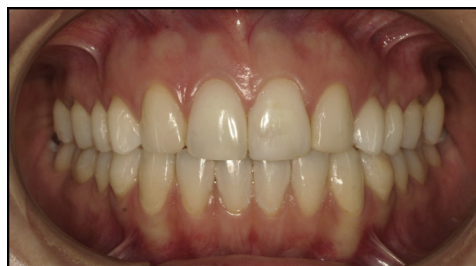The mean age of the respondent groups was comparable, with mean ages of 37.9 years (SD  $\pm$  9.4) for orthodontists and 32.2 years (SD  $\pm$  8.1) for dentists and at least 6 years of professional experience in their fields. The laypersons (mean age, 39 years; SD  $\pm$  8.7) were patients and their relatives from the authors' offices. Informed consent was obtained from all respondents.

No examples of Maryland bridges for prosthodontic replacement were included in this study, because preservation of the alveolar crest with a natural-looking bony contour and a perfect emergence profile are crucial for long-term stability of both pink and white esthetics but hardly achievable with any kind of bridge work.

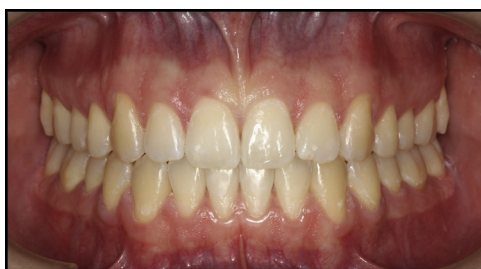All photographs were taken 12 to 24 months after completion of orthodontic treatment and any restorative



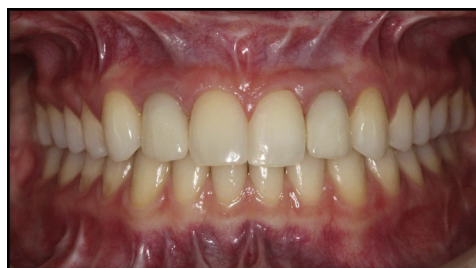**Fig 1.** Space closure with canine substitution for a missing maxillary right lateral incisor and compensatory extraction of the maxillary left first premolar. The right canine has undergone enameloplasty, bleaching, and composite bonding.



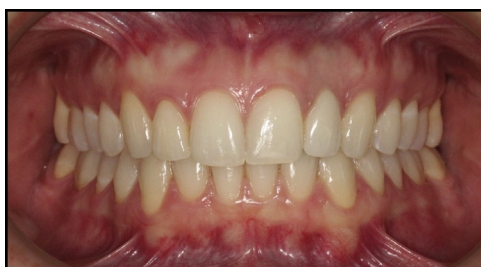**Fig 4.** Space closure with bilateral canine substitutions of the missing maxillary lateral incisors. The maxillary canines have undergone enameloplasty, bleaching, and composite bonding.



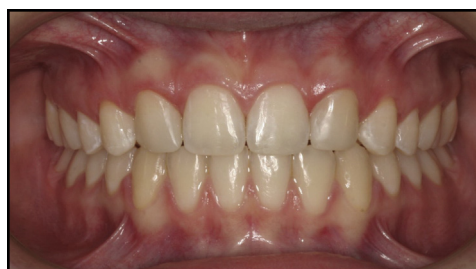**Fig 2.** Normal dentition with no missing teeth.



**Fig 5.** Bilateral implant-borne crowns replacing both maxillary lateral incisors.



**Fig 3.** Implant-borne crown replacing the maxillary left lateral incisor.



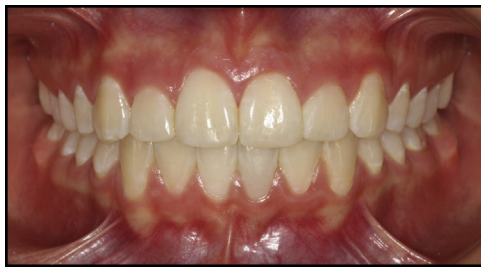**Fig 6.** Bilateral space closure with canine substitutions of the missing maxillary lateral incisors. The canines have undergone enameloplasty, bleaching, and composite bonding.

dental work with the same digital camera with a resolution of  $1280 \times 960$  pixels and matched in size and color using Dolphin software (version 11.7; Dolphin Imaging and Management Systems, Chatsworth, Calif).

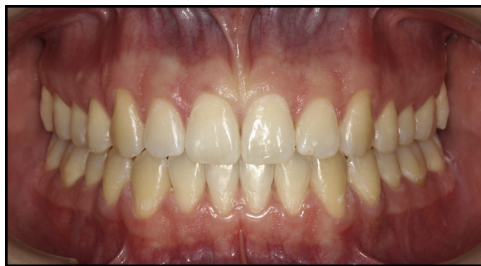Intraoral photographs were printed in  $3.5 \times 5$ -in format with the same ink-jet printer on premium-quality glossy photo paper, using the 1400-dpi print mode for presentation to the panel. No respondent received any additional information about the agenesis or the type of treatment provided.

To measure the esthetic appeal of the treatment results independently of one another, a questionnaire with a fixed set of 7 bipolar adjective pairs for each

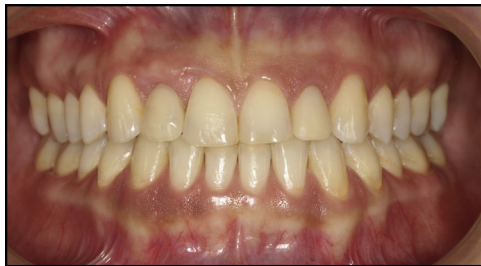photograph was used, as suggested by Bishara and Jakobsen.<sup>29</sup> The 7 pairs were good-bad, satisfactory-unsatisfactory, usual-unusual, nice-awful, attractive-unattractive, beautiful-ugly, and pleasant-unpleasant with a ranking from 1 (best) to 5 (worst) for each pair of adjectives. For each of the 9 photographs, the best possible score was 7, and the worst score was 35 points. Each rater was asked to circle the number that expressed his or her feeling toward the photograph most appropriately at that moment. To prevent acquiescence bias, the



**Fig 7.** Normal dentition with no missing teeth.



**Fig 8.** Normal dentition with no missing teeth.



**Fig 9.** Unilateral implant-borne crown replacing the missing maxillary right lateral incisor.

adjective pairs were arranged according to a random number table as described by Armbruster et al.<sup>27,28</sup> The questionnaires were distributed and completed by dentists and orthodontists attending national dental and orthodontic meetings, with permission from the organizing committees, and by randomly selected patients and their relatives with different socioeconomic (middle to upper class) and educational backgrounds (high school and university diplomas) from the authors' orthodontic offices. All respondents were of the same race, ethnicity, and culture.

### Statistical analysis

The sum for the 3 photographs in each category (space closure with canine substitution, space opening and

prosthetic replacement, and no missing teeth) was averaged, and these values were used for data analysis. Normality of the data was verified with the D'Agostino-Pearson test and equality of variance was assessed with the Levene test. Subsequently, repeated-measures analysis of variance (ANOVA) (factor for repeated measures: treatment modality) and Tukey post hoc tests were performed. All data with a  $P < 0.05$  were considered statistically significant. Data were expressed as means and standard errors. The Levene test was performed with SPSS software (version 22.0; IBM, Armonk, NY), and the other analyses were carried out with Prism (version 6.0; GraphPad Software, La Jolla, Calif).

According to Cohen,<sup>30</sup> the sample size for an ANOVA with 3 groups, setting the  $\alpha$  level at 0.05, with power of 0.8 and a medium effect size, should be 52. With a minimum of 87 respondents in each group, the analysis had at least a power of 0.8.

### RESULTS

For the intragroup rating, the esthetic scores for the various treatment options differed significantly between the 3 respondent groups.

The orthodontists ranked the dentition with no missing teeth as significantly more pleasing ( $12.84 \pm 0.43$ ) than both implants ( $15.9 \pm 0.56$ ;  $P < 0.0001$ ) and space closure with canine substitution ( $17.25 \pm 0.51$ ;  $P < 0.001$ ). There was no statistical difference regarding their preference for either space opening or closure.

The dentists also preferred a dentition with no missing teeth ( $13.35 \pm 0.49$ ;  $P < 0.05$ ) to either space closure with canine substitution ( $15.38 \pm 0.59$ ) or implant-borne crowns ( $15.12 \pm 0.61$ ), but with no statistically different preference between the latter.

The laypersons preferred space closure to space opening ( $13.97 \pm 0.53$  vs  $16.19 \pm 0.61$ ;  $P < 0.01$ ). They judged space closure and canine substitution even better than a dentition with no missing teeth ( $14.71 \pm 0.55$ ), although this difference was statistically not significant (Tables I and II).

For the intergroup rating, both dentists ( $P < 0.05$ ) and laypersons ( $P < 0.0001$ ) preferred space closure with canine substitution to prosthodontic replacement of the missing maxillary lateral incisors compared with the orthodontists.

The orthodontists had a significant preference for a dentition with no missing teeth compared with the laypersons ( $P < 0.05$ ).

No statistically significant difference between the respondent groups was found for the esthetic appeal of implant-borne crowns (Table III).



**Table I.** Means and standard errors for respondents' rankings of the photographs grouped by treatment options

Respondent group	Canine substitution	Implant	No missing teeth
Orthodontists (n = 87)	17.25 ± 0.51	15.90 ± 0.56	12.84 ± 0.43
Dentists (n = 100)	15.38 ± 0.59	15.12 ± 0.61	13.35 ± 0.49
Laypersons (n = 100)	13.97 ± 0.53	16.19 ± 0.61	14.71 ± 0.55

A higher score indicates a less favorable evaluation; the best possible score is 7, and the worst possible is 35.

Compared with the study of Armbruster et al<sup>27,28</sup> in 2005, our overall scores decreased for all 3 treatment modalities, with the exception of a slight, but non-significant, worsening of the orthodontists' perceptions of space closure (Table IV).

The greatest and statistically highly significant improvements were found for the esthetic rating of implant-borne crowns in all 3 respondent groups (orthodontists, 15.90 ± 0.56 vs 22.18 ± 0.57; dentists, 15.12 ± 0.61 vs 21.81 ± 0.30; laypersons, 16.19 ± 0.61 vs 21.52 ± 0.58;  $P < 0.0001$ ).

Space closure with canine substitution was judged similarly by orthodontists and dentists in both studies, whereas laypersons rated the outcome more esthetically pleasing than in 2005 (13.97 ± 0.53 vs 17.44 ± 0.87;  $P < 0.05$ ).

## DISCUSSION

In recent times, esthetic perceptions of the smile have been evaluated relatively frequently among professionals and laypersons, mostly by using a visual analog scale when presenting either a computer-manipulated photograph<sup>31-36</sup> or an altered ideal model (drawing) of a smile to the panel.<sup>37</sup> Respondents with no training might find it difficult to rate these rather artificial representations of dentofacial features, and this may lead to unreliable results. On the other hand, respondents assessing smiles from photographs of the lower facial third may be distracted by adjacent structures such as nose, lips, or skin qualities.<sup>25,33-36</sup>

The intent of our survey was to evaluate differences in the esthetic perceptions of implant-borne crowns for replacement of congenitally missing maxillary lateral incisors and space closure with canine substitution by orthodontists, dentists, and laypersons by showing frontal dental views of treated patients to the respondents. The panel was asked to focus only on the pink and white esthetics of the posttreatment anterior dentition without being distracted by any perioral or facial features. To our knowledge, the only comparable study that used

**Table II.** Intragroup mean differences and 95% confidence intervals (CI) of treatment preferences

ANOVA + Tukey post hoc test	Mean difference	95% CI of difference	Significance
<b>Orthodontists</b>			
Canine substitution vs implant	1.35	0.42 to 2.28	*
Canine substitution vs no missing teeth	4.41	3.48 to 5.34	‡
Implant vs no missing teeth	3.06	2.13 to 3.99	‡
<b>Dentists</b>			
Canine substitution vs implant	0.26	-0.68 to 1.13	NS
Canine substitution vs no missing teeth	2.03	1.16 to 2.89	‡
Implant vs no missing teeth	1.77	0.9 to 3.55	‡
<b>Laypersons</b>			
Canine substitution vs implant	-2.22	-3.09 to -1.35	‡
Canine substitution vs no missing teeth	-0.74	-1.16 to 0.12	NS
Implant vs no missing teeth	1.48	-0.61 to 2.34	†

\* $P < 0.01$ ; † $P < 0.001$ ; ‡ $P < 0.0001$ .  
NS, Nonsignificant.

intraoral photographs of treatment outcomes in clinical patients with unilateral or bilateral agenesis of the maxillary lateral incisors is that by Armbruster et al.<sup>27,28</sup> Orthodontically treated dentitions with no missing teeth served as controls. We were interested to know whether a comparable survey in 2015 would corroborate the findings from 2005. As in the survey of Armbruster et al, instead of a visual analog scale ranking, the respondents were asked to express their feelings using 7 pairs of bipolar adjective for each photograph, because previous research has shown that raters tend to avoid the far ends of the visual analog scale, regardless of their actual preferences.<sup>38</sup>

The number of respondents in each of the 3 categories was more homogenous (87 orthodontists, 100 dentists, 100 laypersons) than in the study by Armbruster et al<sup>27,28</sup> (43 orthodontists, 140 dentists, 40 laypersons) and thus more appropriate for statistical analysis. As in the former study, our respondent sample was not completely random and may not reflect a reliable cross-section of the population, because the orthodontists and the dentists were surveyed at 2 national professional meetings, and the laypersons were patients and their relatives from the authors' offices. Age range and ethnicity of the 3 respondent groups and the work expertise of the dental professionals were

**Table III.** Mean differences and 95% confidence intervals (CI) for treatment preferences between the different respondent groups

ANOVA + Tukey post hoc test	Mean difference	95% CI of difference	Significance
<b>Canine substitution</b>			
Dentists vs laypersons	1.41	−0.01 to 2.83	NS
Dentists vs orthodontists	−1.87	−3.34 to −0.40	*
Laypersons vs orthodontists	−3.28	−4.75 to −1.81	†
<b>Implant</b>			
Dentists vs laypersons	−1.07	−2.49 to 0.35	NS
Dentists vs orthodontists	−0.78	−2.25 to 0.69	NS
Laypersons vs orthodontists	0.29	−1.18 to 1.76	NS
<b>No missing teeth</b>			
Dentists vs laypersons	−1.36	−2.78 to 0.06	NS
Dentists vs orthodontists	0.51	−0.96 to 1.98	NS
Laypersons vs orthodontists	1.87	0.40 to 3.34	*

\* $P < 0.01$ ; † $P < 0.0001$ .

NS, Nonsignificant.

comparable, but the socioeconomic backgrounds of the surveyed laypersons were different. However, all surveyed laypersons were at least high school graduates, and all were able to afford orthodontic treatment, which in our area is on a completely private basis. Whether the level of education or the socioeconomic status plays a significant role in the perception of esthetics has been subject to intense research but has only led to contrasting evidence.<sup>39–43</sup> We doubt that the socioeconomic status of our layperson group had a major influence on the results, since the differences were mild to moderate. No evaluation of the esthetic perceptions between male and female respondents was performed; this could be interesting for a future survey, because the evidence in the literature is conflicting.<sup>44–49</sup>

In all 3 respondent groups, we found a significant improvement of the scores compared with those of Armbruster et al<sup>27,28</sup> in 2005; the scores show that nowadays, better esthetic treatment outcomes in patients with congenitally missing maxillary lateral incisors can be achieved. Only the orthodontists did not perceive recent space closure treatment results as more esthetically pleasing than 10 years ago, probably because denticuring, bleaching, and veneering were already common procedures in the treatment of patients with missing maxillary lateral incisors and produced excellent esthetic treatment outcomes.

**Table IV.** Comparison between the means and standard errors for the rankings of the treatment options

Respondent category	Canine as lateral incisor	Implant	No missing teeth
Orthodontists 2005 (n = 43)	16.24 ± 0.68	22.18 ± 0.57	14.55 ± 0.83
Orthodontists 2015 (n = 87)	17.25 ± 0.51	15.90 ± 0.56	12.84 ± 0.43
Dentists 2005 (n = 140)	17.03 ± 0.74	21.81 ± 0.30	16.79 ± 0.82
Dentists 2015 (n = 100)	15.38 ± 0.59	15.12 ± 0.61	13.35 ± 0.49
Laypersons 2005 (n = 40)	17.44 ± 0.87	21.52 ± 0.58	19.21 ± 0.95
Laypersons 2015 (n = 100)	13.97 ± 0.53	16.19 ± 0.61	14.71 ± 0.55

A higher score indicates a less favorable evaluation; the best possible score is 7, and the worst possible is 35.

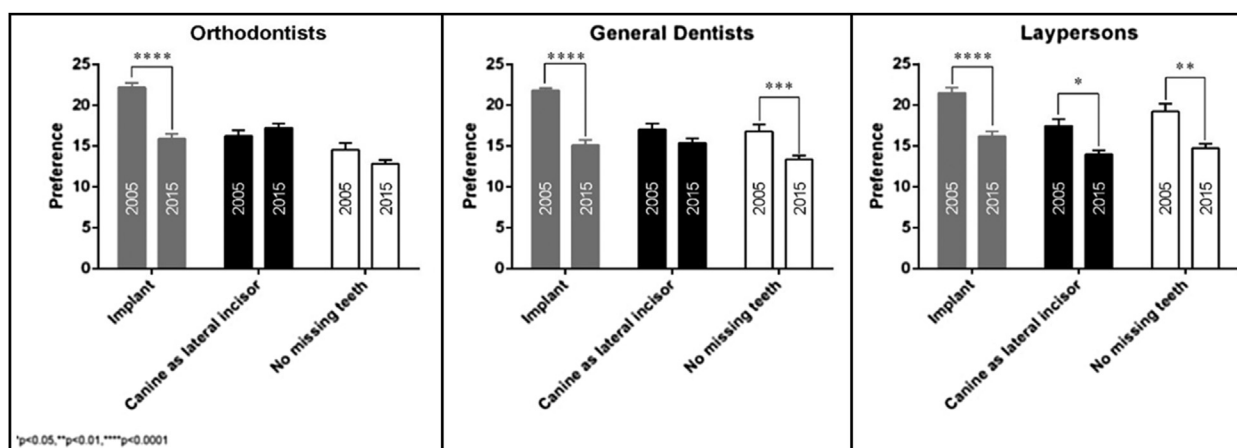
**Table V.** Mean differences and 95% confidence intervals (CI) between treatment preferences among orthodontists, dentists, and laypersons between 2005 and 2015

ANOVA + Tukey post hoc test	Mean difference	95% CI of difference	Significance
<b>Canine substitution</b>			
Orthodontists 2005 vs 2015	−1.01	−4.267 to 2.247	NS
Dentists 2005 vs 2015	1.65	−0.638 to 3.938	NS
Laypersons 2005 vs 2015	3.47	0.201 to 6.739	*
<b>Implant</b>			
Orthodontists 2005 vs 2015	6.28	3.023 to 9.537	§
Dentists 2005 vs 2015	6.69	4.402 to 8.978	§
Laypersons 2005 vs 2015	5.33	2.061 to 8.599	§
<b>No missing teeth</b>			
Orthodontists 2005 vs 2015	1.71	−1.547 to 4.967	NS
Dentists 2005 vs 2015	3.44	1.152 to 5.728	‡
Laypersons 2005 vs 2015	4.5	1.231 to 7.769	†

\* $P < 0.05$ ; † $P < 0.01$ ; ‡ $P < 0.001$ ; § $P < 0.0001$ .

NS, Nonsignificant.

The greatest improvements between 2005 and 2015 could be shown for the replacement of missing maxillary lateral incisors with implant-borne crowns. These statistically highly significant differences ( $P < 0.0001$ ) reflect the recent achievements in periodontology, implantology, prosthodontics, and interdisciplinary therapy, which aims to optimize both pink and white esthetics of implant-supported prosthodontic replacements, especially in the maxillary incisor area.



**Fig 10.** Comparison between the judgments of different treatment outcomes in the 3 respondent groups between 2005 and 2015. \* $P < 0.05$ ; \*\* $P < 0.01$ ; \*\*\* $P < 0.001$ ; \*\*\*\* $P < 0.0001$ .

In contrast to the study by Armbruster et al,<sup>27,28</sup> we could evaluate a trend for orthodontists and dentists to prefer space opening and implant replacement to space closure with canine substitution, although the difference between these treatment options was not statistically significant.

However, both professional groups rated a natural dentition with no missing teeth the most attractive treatment outcome possible. The orthodontists especially had a high preference for a natural dentition, probably because they have extremely keen eyes for even slight deviations from the so-called esthetic norms. This preference was already reported in 2005<sup>27,28</sup> (Table V; Fig 10).

In our survey, the 100 laypersons seemed to have a different perception of dental esthetics compared with the orthodontists and dentists, because they ranked canine substitution for missing maxillary lateral incisors as the best category, even ahead of the natural dentition with no missing teeth, although this trend was not statistically significant. Interestingly, Armbruster et al<sup>27,28</sup> reported the same trend in 2005. Previous surveys have already determined that the general population is less tolerant of reductions in maxillary lateral incisor width and that the golden proportion of 62% between the maxillary central and lateral incisors might need to be adjusted to 70% to 80%, especially when the clinical crown heights are short.<sup>31,32,35</sup> In studies by Pini et al,<sup>50,51</sup> tooth widths and heights in patients with congenitally missing maxillary lateral incisors treated with recontouring were found to be larger than those of patients without agenesis. According to the authors, this was attributed to the fact that orthodontic treatment with conversion of the canines into lateral

incisors usually requires recontouring of the other anterior teeth, such as the central incisors, to obtain better harmony of the smile; this is corroborated in the study of Rosa et al.<sup>37</sup>

When the laypersons in our survey were asked why they preferred the esthetic outcome of space closure with canine substitution even to dentitions with no missing teeth, answers such as “the 4 front teeth appear more equal,” “it looks more symmetrical,” and “the mouth is less toothy” were common. More than 35 years ago, a study by Brisman<sup>52</sup> showed already significant differences in esthetic preferences of tooth shapes and arrangements between patients, dental students, and dentists. In this study, the laypeople preferred a maxillary canine-to-canine composition with larger lateral incisors and more or less even incisal margins (“piano key” or “picket fence”). We can deduce that our professional code of esthetics and sense of proportion may differ from laypersons’ and patients’ perceptions of attractiveness. Although orthodontists and dentists are trained to respect the Bolton index and to create golden interdental and intradental proportions, our patients might prefer bigger or same-size lateral incisors.

Research has shown that tooth color is of primary importance for esthetic satisfaction with treatment outcomes for laypersons. Although efforts were made to calibrate the colors in the 9 photographs, an overall darker tooth shade of the 3 implant patients may have contributed to the poorer esthetic ranking of these treatment results in the layperson group.<sup>46-49,53,54</sup> The 3 patients who received implant-borne crowns were adults between 25 and 33 years of age, whereas the patients with canine substitution or no missing teeth were younger (16-19 years).

A recent study by Mehl et al<sup>55</sup> also aimed to determine dentists', dental students', and patients' levels of satisfaction after full-mouth restorations with veneers and crowns including anterior teeth. The authors found significant differences in the judgments of the severity of the initial dental appearance and the esthetic perceptions of the final treatment outcomes. Hence, showing photographs of what professionals consider to be "esthetically pleasing treatment results" to patients with missing maxillary lateral incisors during treatment planning can be of help for improving doctor-patient communications and a better understanding of patients' expectations. However, the esthetic impact of a detailed dental view decreases in a full facial smile view.<sup>40</sup> Therefore, apart from mere esthetic considerations, it is also our professional duty to critically inform the patient about any potential issues with implant-borne crowns after space opening or multiple veneer restorations after space closure in the long-term, especially because scientific evidence for both treatment types is still lacking.<sup>56</sup>

## CONCLUSIONS

Although the esthetic outcomes of implant-borne crowns replacing missing maxillary lateral incisors are far more appealing than they were 10 years ago, esthetic perceptions and preferences for this treatment modality can vary between dental professionals and laypersons.

In the absence of randomized controlled trials about long-term esthetic and functional stability of standard treatment modalities for agenesis of the maxillary lateral incisors, dental professionals should refrain from imposing their esthetic preferences on patients.

## REFERENCES

- Goodman JR, Jones SP, Hobkirk JA, King PA. Hypodontia: clinical features and the management of mild to moderate hypodontia. *Dent Update* 1994;21:381-4.
- Polder BJ. A meta-analysis of the prevalence of dental agenesis of permanent teeth. *Community Dent Oral Epidemiol* 2004;32:217-26.
- Lamour CI, Mossey PA, Thind BS, Forgie AH, Stirrups DR. Hypodontia—a retrospective review of prevalence and etiology. Part I. *Quintessence Int* 2005;36:263-70.
- Rakhshan V. Meta-analysis and systematic review of factors biasing the observed prevalence of congenitally missing teeth in permanent dentition excluding third molars. *Prog Orthod* 2013;14:33-44.
- Johal A, Katsaros C, Kuijpers-Jagtman AM. Angle Society of Europe membership. State of the science on controversial topics: missing maxillary lateral incisors—a report of the Angle Society of Europe 2012 meeting. *Prog Orthod* 2013;14:20.
- Zachrisson B, Rosa M, Toreskog S. Congenitally missing maxillary lateral incisors: canine substitution. *Am J Orthod Dentofacial Orthop* 2011;139:435-44.
- Kokich VG. Maxillary lateral incisor implants: planning with the aid of orthodontics. *Int J Oral Maxillofac Surg* 2004;62:48-56.
- Kokich VO, Kinzer GA, Janakievski J. Congenitally missing maxillary lateral incisors: restorative replacement. *Am J Orthod Dentofacial Orthop* 2011;139:435-45.
- Ostler MS, Kokich VG. Alveolar ridge changes in patients congenitally missing mandibular second premolars. *J Prosthet Dent* 1994;71:144-9.
- Henry PH, Laney WR, Jemt T, Harris D, Krogh PH, Polizzi G, et al. Osseointegrated implants for single tooth replacement: a prospective 5-year multicenter study. *Int J Oral Maxillofac Implants* 1996;11:450-5.
- Garber DA, Salama MA, Salama H. Immediate total tooth replacement. *Compend Contin Educ Dent* 2001;22:210-6:218.
- Sabri R. Management of missing maxillary lateral incisors. *J Am Dent Assoc* 1999;130:80-4.
- Grunder U, Gracis S, Capelli M. Influence of the 3-D bone-to-implant relationship on esthetics. *Int J Periodontics Restor Dent* 2005;25:113-9.
- Giannopoulou C, Bernard JP, Buser D, Carrel A, Belser UC. Effect of intracrevicular restoration margins on peri-implant health: clinical, biochemical, and microbiologic findings around esthetic implants up to 9 years. *Int J Oral Maxillofac Implants* 2003;18:173-81.
- Buser D, Bornstein MM, Weber HP, Grütter L, Schmid B, Belser UC. Early implant placement with simultaneous guided bone regeneration following single-tooth extraction in the esthetic zone: a cross-sectional, retrospective study in 45 subjects with a 2- to 4-year follow-up. *J Periodontol* 2008;79:1773-81.
- Buser D, Halbritter S, Hart C, Bornstein MM, Grutter L, Chappuis V, et al. Early implant placement with simultaneous guided bone regeneration following single-tooth extraction in the esthetic zone: 12-month results of a prospective study with 20 consecutive patients. *J Periodontol* 2009;80:152-62.
- Schneider-Moser U, Moser L, Pellitteri G. To open or to close spaces for congenitally missing upper lateral incisors: is this really the question? *EJCO* 2013;1:32-43.
- Mayer TM, Hawley CE, Gunsolley JC, Feldman S. The single-tooth implant: a viable alternative for single-tooth replacement. *J Periodontol* 2002;73:687-93.
- Thilander B, Odman J, Lekholm U. Orthodontic aspects of the use of oral implants in adolescents: a 10-year follow-up study. *Eur J Orthod* 2001;23:715-31.
- Jemt T, Ahlberg G, Henriksson K, Bondevik O. Changes of anterior clinical crown height in patients provided with single-implant restorations after more than 15 years of follow-up. *Int J Prosthodont* 2006;19:455-61.
- Bernard JP, Schatz JP, Christou P. Long-term vertical changes of the anterior maxillary teeth adjacent to single implants in young and mature adults: a retrospective study. *J Clin Periodontol* 2004;31:1024-8.
- Forsberg CM, Eliasson S, Westergren H. Face height and tooth eruption in adults: a 20-year follow-up investigation. *Eur J Orthod* 1991;13:249-54.
- Nordquist GG, McNeill RW. Orthodontic vs. restorative treatment of the congenitally absent lateral incisors—long-term periodontal and occlusal evaluation. *J Periodontol* 1975;46:139-43.
- Robertsson S, Mohlin B. The congenitally missing upper lateral incisor. A retrospective study of orthodontic space closure versus restorative treatment. *Eur J Orthod* 2000;22:697-710.
- De-Marchi LM, Pini NI, Ramos AL, Pascotto RC. Smile attractiveness of patients treated for congenitally missing maxillary lateral



- incisors as rated by dentists, laypersons, and the patients themselves. *J Prosthet Dent* 2014;112:540-6.
26. Jamilian A, Perillo L, Rosa M. Missing upper incisors: a retrospective study of orthodontic space closure versus implant. *Prog Orthod* 2015;16:2.
  27. Armbruster PC, Gardiner DM, Whitley JB Jr, Flerra J. The congenitally missing maxillary lateral incisor. Part 1: esthetic judgement of treatment options. *World J Orthod* 2005;6:369-75.
  28. Armbruster PC, Gardiner DM, Whitley JB Jr, Flerra J. The congenitally missing maxillary lateral incisor. Part 2: assessing dentists' preferences for treatment. *World J Orthod* 2005;6:376-81.
  29. Bishara SE, Jakobsen JR. Profile changes in patients treated with and without extractions: assessments by laypeople. *Am J Orthod Dentofacial Orthop* 1997;112:639-44.
  30. Cohen JA. power primer. *Psychol Bull* 1992;112:155-9.
  31. Rosenstiel SF, Ward DH, Rashid RG. Dentists' preferences of anterior tooth proportion—a Web-based study. *J Prosthodont* 2000;9:123-36.
  32. Bukhary SM, Gill DS, Tredwin CJ, Moles DR. The influence of varying lateral incisor dimensions on perceived smile aesthetics. *Br Dent J* 2007;203:687-92.
  33. Ker AJ, Chan R, Fields HW, Beck M, Rosenstiel S. Esthetics and smile characteristics from the laypersons's perspective: a computer-based survey study. *J Am Dent Assoc* 2008;139:1318-27.
  34. McLeod C, Fields HW, Hechter F, Wiltshire W, Rody W Jr, Christensen J. Esthetics and smile characteristics evaluated by laypersons. *Angle Orthod* 2011;81:198-205.
  35. Borges AC, Seixas MR, Machado AW. Influence of different width/height ratio maxillary anterior teeth in the attractiveness of gingival smiles. *Dental Press J Orthod* 2012;17:115-22.
  36. Cotrim ER, Vasconcelos Júnior AV, Haddad AC, Reis SA. Perception of adults' smile esthetics among orthodontists, clinicians and laypeople. *Dental Press J Orthod* 2015;20:40-4.
  37. Rosa M, Olimpo A, Fastuca R, Caprioglio A. Perceptions of dental professionals and laypeople to altered dental aesthetics in cases with congenitally missing maxillary lateral incisors. *Prog Orthod* 2013;14:34-40.
  38. Schnabel BJ, McNamara JA Jr, Franchi L, Baccetti T. Q-sort assessment vs visual analog scale in the evaluation of smile esthetics. *Am J Orthod Dentofacial Orthop* 2009;135(Suppl 4):S61-71.
  39. Thomas JL, Hayes C, Zawaideh S. The effect of axial midline angulation on dental esthetics. *Angle Orthod* 2003;73:359-64.
  40. Flores-Mir C, Silva E, Barriga MI, Lagravère MO, Major PW. Laypersons' perception of smile esthetics in dental and facial views. *J Orthod* 2004;31:204-9.
  41. Flores-Mir C, Silva E, Barriga MI, Valverde RH, Lagravère MO, Major PW. Laypersons' perceptions of the esthetics of visible anterior occlusion. *J Can Dent Assoc* 2005;71:849.
  42. Tickle M, Kay EJ, Beam D. Socio-economic status and orthodontic treatment need. *Community Dent Oral Epidemiol* 1999;27:413-8.
  43. Chia RC, Allred LJ, Grossnickle WF, Lee GW. Effects of attractiveness and gender on the perception of achievement-related variables. *J Soc Psychol* 1998;138:471-7.
  44. Kerns LL, Silveira AM, Kerns DG, Regennitter FJ. Esthetic preference of the frontal and profile views of the same smile. *J Esthet Dent* 1997;9:76-85.
  45. Badran SA, Mustafa M. Perception of smile attractiveness by laypeople—influence of profession and treatment experience. *Br J Med Medical Res* 2014;4:3777-86.
  46. Vallittu PK, Vallittu AS, Lassila VP. Dental aesthetics—a survey of attitudes in different groups of patients. *J Dent* 1996;24:335-8.
  47. Carlsson GE, Wagner IV, Odman P, Ekstrand K, MacEntree M, Marinello C, et al. An international comparative multicenter study of assessment of dental appearance using computer-aided image manipulation. *Int J Prosthodont* 1998;11:246-54.
  48. Shulman JD, Maupome G, Clark DC, Levy SM. Perceptions of desirable tooth color among parents, dentists and children. *J Am Dent Assoc* 2004;135:595-604.
  49. Tin-Oo MM, Saddki N, Hassan N. Factors influencing patient satisfaction with dental appearance and treatments they desire to improve aesthetics. *BMC Oral Health* 2011;11:6.
  50. Pini NP, de-Marchi LM, Gribel BF, Ubal dini AL, Pascotto RC. Analysis of the golden proportion and width/height ratios of maxillary anterior dentition in patients with lateral incisor agenesis. *J Esthet Restor Dent* 2012;24:402-14.
  51. Pini NI, Marchi LM, Pascotto RC. Congenitally missing maxillary lateral incisors: update on the functional and esthetic parameters of patients treated with implants or space closure and teeth recontouring. *Open Dent J* 2015;8:289-94.
  52. Brisman AS. Esthetics: a comparison of dentists' and patients' concepts. *J Am Dent Assoc* 1980;100:345-52.
  53. Samorodnitzky-Naveh GR, Geiger SB, Levin L. Patients' satisfaction with dental esthetics. *J Am Dent Assoc* 2007;138:805-8.
  54. Van der Geld P, Oosterveld P, Van Heck G, Kuijpers-Jagtman AM. Smile attractiveness. *Angle Orthod* 2007;77:759-65.
  55. Mehl CJ, Harder S, Wolfart S, Vollrath O, Trinkler A, Wenz HJ, et al. Influence of dental education on esthetic perception. *Int J Esthet Dent* 2015;10:486-99.
  56. Andrade DC, Loureiro CA, Araújo VE, Riera R, Atallah AN. Treatment for agenesis of maxillary lateral incisors: a systematic review. *Orthod Craniofac Res* 2013;16:129-36.